

Retropharyngeal Abscess Presenting as Leptomeningeal Meningitis: A Diagnostic Challenge

Abcesso Retrofaríngeo Apresentando-se como Meningite Leptomeníngea: Um Desafio Diagnóstico

Joana Tavares Pereira¹, Alexandra Pousinha², Marcos Gil da Veiga³, Carla Tonel¹

Corresponding author/Autor Correspondente:

Joana Tavares Pereira [joanaitpereira@gmail.com]

ORCID: <https://orcid.org/0000-0002-1424-3746>

Internal Medicine Department, Unidade Local de Saúde Estuário do Tejo, Hospital de Vila Franca de Xira, Lisboa, Portugal.

Estrada Carlos Lima Costa N° 2, Povos 2600-009, Vila Franca de Xira

DOI: <https://doi.org/10.29315/gm.1007>

KEYWORDS: Meningitis, Bacterial; Osteomyelitis; Retropharyngeal Abscess/diagnostic imaging

PALAVRAS-CHAVE: Abcesso Retrofaríngeo/diagnóstico por imagem; Meningite Bacteriana; Osteomielite

A 50-year-old female with a known history of type 2 diabetes presented to the Emergency Department (ED) with cervical pain, fever and confusion. Over the previous week, she had become progressively more confused and with low-grade fever. The pain had started three weeks earlier, and worsened despite taking analgesics prescribed during previous ED visits. Additionally, one month earlier, she had complained of odynophagia following an episode of choking on a chicken bone.

Upon admission, the patient was febrile (38.6°C) and disoriented, with a Glasgow Coma Scale (GCS) score of 14. Physical examination revealed neck rigidity. Laboratory tests showed leukocytosis ($24.8 \times 10^3/\mu\text{L}$; reference range [RR]: $4.0\text{--}10.0 \times 10^3/\mu\text{L}$), with a predominance of neutrophils ($22.2 \times 10^3/\mu\text{L}$; RR: $2.0\text{--}7.0 \times 10^3/\mu\text{L}$), and an elevated C-reactive protein level (23.8 mg/dL; RR: <1

mg/dL). A head computed tomography (CT) scan revealed no abnormalities. Lumbar puncture was suggestive of bacterial meningitis. Empiric treatment with meningeal-dose ceftriaxone and ampicillin was initiated.

On the second day of admission, the patient's neurological status deteriorated, with her GCS score dropping to 10. A contrast-enhanced head and neck CT scan revealed a large foreign body of bone density, accompanied by an abscess in the retropharyngeal space, erosive changes in the first two cervical vertebrae and findings consistent with cervical leptomeningitis (Figs. 1 and 2). Despite aggressive treatment, the patient developed septic shock, which progressed to refractory shock, ultimately resulting in her death.

Retropharyngeal abscess is a rare but potentially life-threatening infection that can be triggered by trauma to the posterior pharynx.^{1,2} Early diagnosis is

1. Internal Medicine Department, Unidade Local de Saúde Estuário do Tejo, Hospital de Vila Franca de Xira, Lisboa, Portugal. 2. Intensive Care Unit, Unidade Local de Saúde Estuário do Tejo, Hospital de Vila Franca de Xira, Lisboa, Portugal. 3. Imagiology Department, Unidade Local de Saúde Estuário do Tejo, Hospital de Vila Franca de Xira, Lisboa, Portugal.

Received/Recebido: 2024-02-05. Accepted/Aceite: 2025-11-13; Published online/Publicado online: 2026-03-06. Published/Publicado: 2026-06-09.

© 2026 Gazeta Médica. This is an open-access article under the CC BY-NC 4.0. Re-use permitted under CC BY-NC 4.0. No commercial re-use.

© 2026 Gazeta Médica. Este é um artigo de acesso aberto sob a licença CC BY-NC 4.0. Reutilização permitida de acordo com CC BY-NC 4.0. Nenhuma reutilização comercial

essential to prevent complications, including cervical osteomyelitis and leptomeningitis, and a contrast-enhanced neck CT scan is the gold standard imaging modality.¹⁻³

A high index of suspicion for neck infections in vulnerable patients presenting with neck pain should be maintained, and the threshold for imaging evaluation lowered.

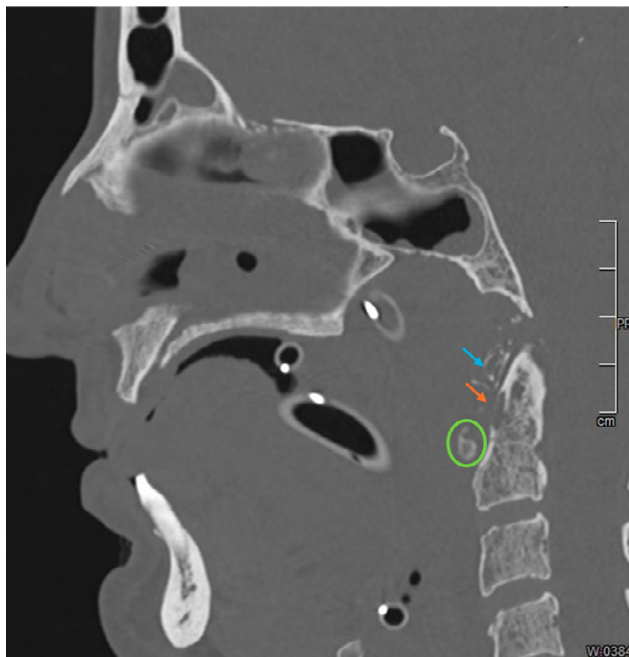


FIGURE 1. Head and neck CT scan - sagittal view: foreign body (green circle) and bone erosion of the atlas' anterior arch (blue arrow) and axis' odontoid process (orange arrow)

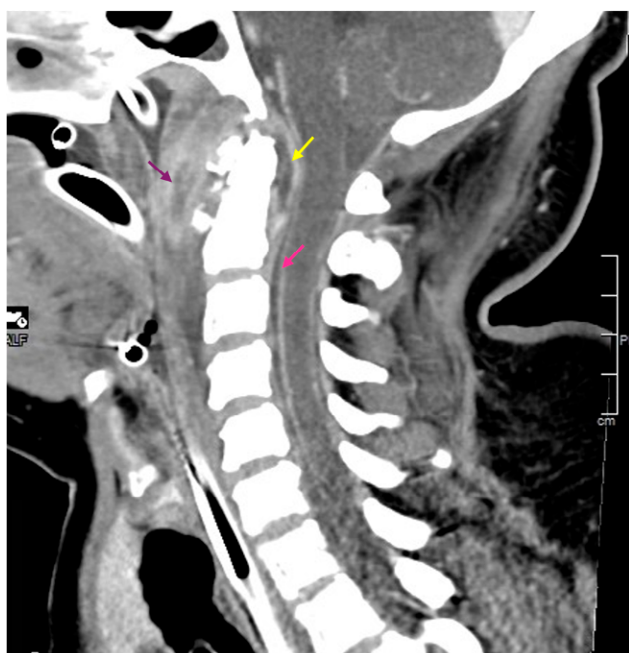


FIGURE 2. Head and neck CT scan sagittal view: perimedullary enhancement suggestive of leptomeningitis (pink arrow), subligamentous abscess (yellow arrow) and thickening and densification of the posterior pharyngeal wall with an abscessed cavity (purple arrow)

CONTRIBUTORSHIP STATEMENT DECLARAÇÃO DE CONTRIBUIÇÃO

JTP, AP, MGV, CT - Drafting of the article and approval of the final version.

All authors approved the final version to be published.

JTP, AP, MGV, CT - Redação do artigo e aprovação da versão final.

Todos os autores aprovaram a versão final a ser publicada

ETHICAL DISCLOSURES

CONFLICTS OF INTEREST: The authors have no conflicts of interest to declare.

FINANCIAL SUPPORT: This work has not received any contribution, grant or scholarship.

CONFIDENTIALITY OF DATA: The authors declare that they have followed the protocols of their work center on the publication of patient data.

PATIENT CONSENT: Consent for publication was obtained.

PROVENANCE AND PEER REVIEW: Not commissioned; externally peer-reviewed.

RESPONSABILIDADES ÉTICAS

CONFLITOS DE INTERESSE: Os autores declaram a inexistência de conflitos de interesse na realização do presente trabalho.

FONTES DE FINANCIAMENTO: Não existiram fontes externas de financiamento para a realização deste artigo.

CONFIDENCIALIDADE DOS DADOS: Os autores declaram ter seguido os protocolos da sua instituição acerca da publicação dos dados de doentes.

CONSENTIMENTO: Consentimento do doente para publicação obtido.

PROVENIÊNCIA E REVISÃO POR PARES: Não comissionado; revisão externa por pares.

REFERENCES

1. Sakthivel P, Yogal R, Verma H, Saini A, Chandran A. Acute Retropharyngeal Abscess Masquerading as Meningitis. *JNMA J Nepal Med Assoc.* 2017;56:186-8. doi: 10.31729/jnma.2993
2. Jain H, Hohman MH, Sinha V. Retropharyngeal Abscess [e-book]. StatPearls; 2024 [accessed 2023 Nov 25]. Available: <https://www.ncbi.nlm.nih.gov/books/NBK441873/>
3. Ku BD, Park KC, Yoon SS. Medically treated deep neck abscess presenting with occipital headache and meningism. *J Headache Pain.* 2008;9:47-50. doi: 10.1007/s10194-008-0005-2