

Tophaceous Gout: A Rare Case, Crucial Lessons

Gota Tofácea: Um Caso Incomum, Lições Fundamentais

Rui Guilherme Costa, Henrique João Correia, Ana Rita Rabaça, Diana Roda

Corresponding Author/Autor Correspondente:

Rui Guilherme Costa - guilherme.90.costa@gmail.com

ORCID: <https://orcid.org/0000-0001-5844-6572>

Unidade Local de Saúde de Coimbra, Unidade de Saúde Familiar

Manuel Cunha, Coimbra, Portugal

Estrada do Espírito Santo das Touregas,

Quinta dos Vales - São Martinho do Bispo - 3045-059 Coimbra

DOI: <https://doi.org/10.29315/gm.1027>

KEYWORDS: Arthritis, Gouty; Gout; Joint Deformities, Acquired

PALAVRAS-CHAVE: Artrite Gotosa; Deformidades Articulares Adquiridas; Gota

We present the case of a 60-year-old male with a history of right partial nephrectomy and post-traumatic splenectomy, arterial hypertension, chronic alcoholism, peripheral arterial disease, chronic kidney disease G3b A1, and polyarticular tophaceous gout, with amputation of the 3rd finger of the right hand due to an infected gouty tophus. During home consultation, prominent gouty tophi and articular deformities were noted on the palmar and dorsal aspects of both hands, as well as articular structural changes and gouty tophi in the medial aspect of both knees, leading to permanent chronic pain and functional disability. Multiple gout flares were described during the course of the disease, mainly treated with colchicine and prednisolone. For chronic hyperuricemia control, he was previously treated with allopurinol 300 mg for several years, which was replaced by febuxostat 80 mg four years ago due to its more favorable pharmacokinetic

profile in the context of chronic kidney disease. Before the initiation of urate-lowering therapy, the patient's serum uric acid levels ranged between 11.2 and 12.5 mg/dL. More recently, he maintained uric acid levels persistently above 8.5 mg/dL despite treatment. This suggested inadequate therapeutic adherence and/or undertreatment, since the previously prescribed dose of allopurinol was well below the maximum daily dose (800 mg). Due to joint pain, he is medicated with tramadol + paracetamol 37.5 + 350 mg twice daily for chronic pain management.

Gout is the most common microcrystalline arthritis, predominantly affecting men over 40 years, which is characterized by deposition of monosodium urate crystals in joints, bones, soft tissues and kidneys.¹ The European prevalence ranges from 0.9% to 2.5%.¹ Nevertheless, large tophi are unusual in chronic gout.² They are observed in individuals with prolonged dis-

Unidade Local de Saúde de Coimbra, Unidade de Saúde Familiar Manuel Cunha, Coimbra, Portugal

Received/Recebido: 2025-03-15. Accepted/Aceite: 2025-08-26. Published online/Publicado online: 2025-11-05. Publicado/Published: 2026-06-09.

© Author(s) (or their employer(s)) and Gazeta Médica 2025. Re-use permitted under CC BY-NC 4.0. No commercial re-use.

© Autor (es) (ou seu (s) empregador (es)) e Gazeta Médica 2025. Reutilização permitida de acordo com CC BY-NC 4.0. Nenhuma reutilização comercial.

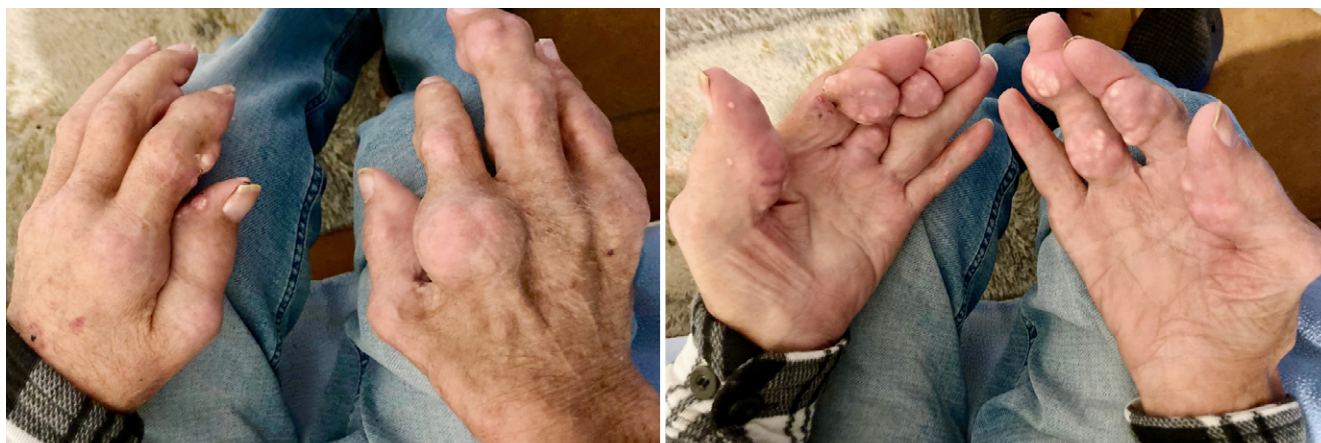

FIGURE 1. Marked joint deformity and multiple bilateral gouty tophi in both hands.

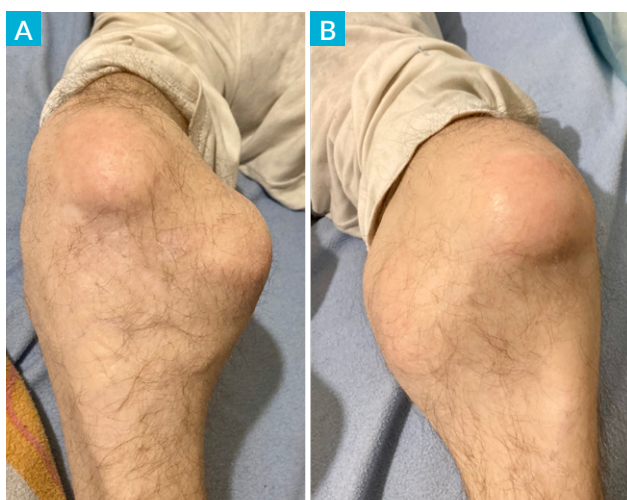


FIGURE 2. Structural deformities and gouty tophi of the medial aspect of both knees. A – Right knee; B – Left knee.

ease, inadequate follow-up and/or non-adherence to prescribed treatment and in chronic kidney disease. The deposition of monosodium urate crystals, resulting from chronic hyperuricemia, triggers the formation of gouty tophi and recurrent acute flares, both contributing to progressive articular damage.³ This clinical presentation demonstrates the progression of polyarticular gout in individuals with poor therapeutic adherence, culminating in functional limitation and chronic pain. The rarity of this clinical case is an opportunity to highlight the importance of early diagnosis, implementation of effective therapy and increased awareness of the disease's impact on quality of life.

CONTRIBUTORSHIP STATEMENT/ DECLARAÇÃO DE CONTRIBUIÇÃO

RC - Seleção e interpretação de imagens e redação do artigo

HC - Revisão de artigo

AR - Seleção e interpretação de imagens e redação de artigo

DR - Revisão de artigo

Todos os autores aprovaram a versão final a ser publicada
RC - Selection and interpretation of images and article writing

HC - Article Review

AR - Selection and interpretation of images and article writing

DR - Article review

All authors approved the final version to be published.

ETHICAL DISCLOSURES

CONFLICTS OF INTEREST: The authors have no conflicts of interest to declare.

FINANCING SUPPORT: This work has not received any contribution, grant or scholarship.

CONFIDENTIALITY OF DATA: The authors declare that they have followed the protocols of their work center on the publication of patient data.

PATIENT CONSENT: Consent for publication was obtained.

PROVENANCE AND PEER REVIEW: Not commissioned; externally peer-reviewed

RESPONSABILIDADES ÉTICAS

CONFLITOS DE INTERESSE: Os autores declaram a inexistência de conflitos de interesse na realização do presente trabalho.

FONTES DE FINANCIAMENTO: Não existiram fontes externas de financiamento para a realização deste artigo.

CONFIDENCIALIDADE DOS DADOS: Os autores declaram ter seguido os protocolos da sua instituição acerca da publicação dos dados de doentes.

CONSENTIMENTO: Consentimento do doente para publicação obtido.

PROVENIÊNCIA E REVISÃO POR PARES: Não comissionado; revisão externa por pares.

REFERENCES

1. Richette P, Doherty M, Pascual E, Barskova V, Becce F, Castaneda J, et al. 2018 updated European League Against Rheumatism evidence-based recommendations for the diagnosis of gout. *Ann Rheum Dis.* 2020;79:31-8. doi: 10.1136/annrheumdis-2019-215315.
2. Aradoini N, Talbi S, Berrada K, Abourazzak FZ, Harzy T. Chronic tophaceous gout with unusual large tophi: case report. *Pan Afr Med J.* 2015;22:132. doi: 10.11604/pamj.2015.22.132.6447.
3. Weaver JS, Vina ER, Munk PL, Klauser AS, Elifritz JM, Taljanovic MS. Gouty Arthropathy: Review of Clinical Manifestations and Treatment, with Emphasis on Imaging. *J Clin Med.* 2021;11:166. doi: 10.3390/jcm11010166.