

Rare Isolated Trapezium Fracture: Clinical Case Presentation

Fratura Rara Isolada do Trapézio: Apresentação de Caso Clínico

Pedro Martins Branco^{1*}, Carolina Baptista², Daniel Mendes³

*Corresponding Author/Autor Correspondente:

Pedro Martins Branco [pmartinsbranco@gmail.com]
Hospital CUF Santarém, Rua Zeferino Silva, Santarém, Portugal
ORCID iD: 0000-0003-4313-9718

RESUMO

As fraturas do trapézio são raras, representando 0,4% das lesões da mão. Uma vez que estas costumam ser imperceptíveis nas radiografias simples, o diagnóstico no contexto de serviço de urgência é desafiante. A tomografia computadorizada pode ser útil no diagnóstico. O tratamento *gold standard* para fraturas do trapézio é discutível.

Um paciente do género masculino, de 54 anos, foi admitido num serviço de urgência após um acidente de motociclo. Referia dor e tumefação na metade radial da mão esquerda, não dominante. As radiografias foram inconclusivas. A tomografia computadorizada e a ressonância magnética revelaram uma fratura isolada do trapézio, com um pequeno fragmento volar coaptado. Pelo nosso conhecimento, este padrão de fratura ainda não foi descrito. O tratamento conservador resultou na união da fratura, com excelente função do polegar, sem complicações.

Este caso destaca a importância de uma elevada suspeita clínica, anamnese cuidadosa, exame físico e interpretação dos exames de imagem para evitar falhar o diagnóstico de uma fratura do trapézio.

PALAVRAS-CHAVE: Fraturas Ósseas/diagnóstico; Trapézio/lesões

ABSTRACT

Isolated trapezium fractures are rare, accounting for 0.4% of the hand injuries. As these injuries are often imperceptible on plain radiographs, diagnosis in the emergency department setting is challenging. Computed tomography scan can be helpful in the diagnosis. The gold standard treatment for trapezium fractures is still debatable.

A 54 years-old male patient presented to an emergency department following a motorcycle accident. He reported pain and swelling on the radial half of his left non-dominant hand. Radiographs were inconclusive. Computed tomography scan and magnetic resonance imaging revealed an isolated trapezium fracture with a non-displaced small volar fragment. To our best knowledge, this fracture pattern has not been reported before. Conservative treatment resulted in union with excellent thumb function and no complications.

This case highlights the importance of a high clinical suspicion, careful history taking, physical examination, and imaging interpretation to avoid missing a trapezium fracture.

KEYWORDS: Fractures, Bone/diagnosis; Trapezium Bone/injuries

1. Hospital CUF Santarém, Santarém, Portugal. 2. Unidade Cuidados Médicos de Acidentes - Fidelidade, Lisboa, Portugal. 3. Hospital CUF Tejo, Lisboa, Portugal.

Received/Recebido: 05/12/2021 - Accepted/Aceite: 17/03/2022 - Published online/Publicado online: 18/05/2022 - Published/Publicado: 30/06/2022

© Author(s) (or their employer(s)) and Gazeta Médica 2022. Re-use permitted under CC BY-NC. No commercial re-use. © Autor (es) (ou seu (s) empregador (es)) e Gazeta Médica 2022. Reutilização permitida de acordo com CC BY-NC. Nenhuma reutilização comercial.

INTRODUCTION

Among different carpal bones, those placed at the proximal row are more prone to fracture.¹ Trapezium fractures are rare, accounting for 0.4% of hand's injuries^{2,3} and 3%-5% of carpal fractures.⁴⁻⁶

Due to the low prevalence and difficulty in diagnosing isolated trapezium fractures by routine imaging, high clinical suspicion, careful history taking, physical examination, and imaging interpretation are needed to avoid missing this diagnosis.¹

A universal protocol for its treatment is lacking.⁷ Several treatment options have been described in the literature.^{3,6,7}

In this paper, we report a case of a 54-year-old male patient with an isolated trapezium fracture following a motorcycle accident. It then further delineates its clinical and radiologic outcomes. Conservative treatment followed by progressive mobilization and strengthening resulted in union with excellent thumb function and no complications. The patient returned to his previous level of activity with an excellent outcome 2.5 months after the injury.

The aim of this report is to increase awareness regarding trapezium fractures, diagnostic tools and to share our treatment experience. It also illustrates a fracture's pattern not mentioned on Walker's classification.

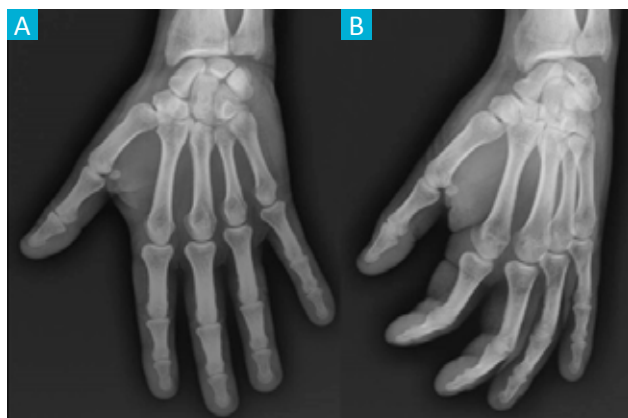


FIGURE 1. Left hand radiographs at presentation in anteroposterior (A) and oblique (B) projections. Both were inconclusive, showing no obvious fractures and intact trapeziometacarpal joint.

CASE REPORT

A 54-year-old informatics engineer male patient presented to the emergency department (ED) on the same day following a motorcycle accident. Mechanism of trauma consisted of falling onto the hand with the extended wrist and the hand in radial deviation. He reported pain and swelling on the radial half of his left non-dominant hand.

On examination there was tenderness over the trapezium, base of first metacarpal and anatomical snuffbox. Thumb motion was slightly painfully inhibited, the maximum pain being produced on marked opposition. His neuro-vascular status was intact. There were no signs of carpal instability. No skin lesions were evident. His past medical and family history, surgical and social history were unremarkable.

Plain radiographs of the left hand were inconclusive (Fig. 1). Because of the amount of pain and the suspiciousness of a carpal injury, a short-arm thumb spica was applied. Two days after, magnetic resonance imaging (MRI) indicated a fracture of the trapezium, with no associated lesions. Computed tomography scan (CT scan) was obtained to further characterize the anatomy of the fracture. It showed a minimally displaced small volar fragment, not mentioned on Walker's classification (Fig. 2). Trapeziometacarpal congruence was evident, and all other carpal bones were intact. To our best knowledge, this fracture pattern has not been reported before.

Fracture was non-displaced, so we decided to keep conservative treatment with a short-arm thumb spica.

Six weeks after the injury, the immobilization was removed, and the patient started physiotherapy to improve range of motion (ROM) and strength.

Two months following the injury, the patient regained a full range of unrestricted, painless thumb movements and full hand function (Fig. 3). There was no local tenderness. The Grind test did not show any joint limitations or pain.

The patient reported satisfactory return to all his normal activities of daily living and returned to work with no limitations 2.5 months after the injury.

At the final follow up - 12 months after the injury - the outcome was excellent and symmetric to the non-injured side. The fracture healed with no complications. His QuickDASH (disabilities of the arm, shoulder and hand) score was zero.

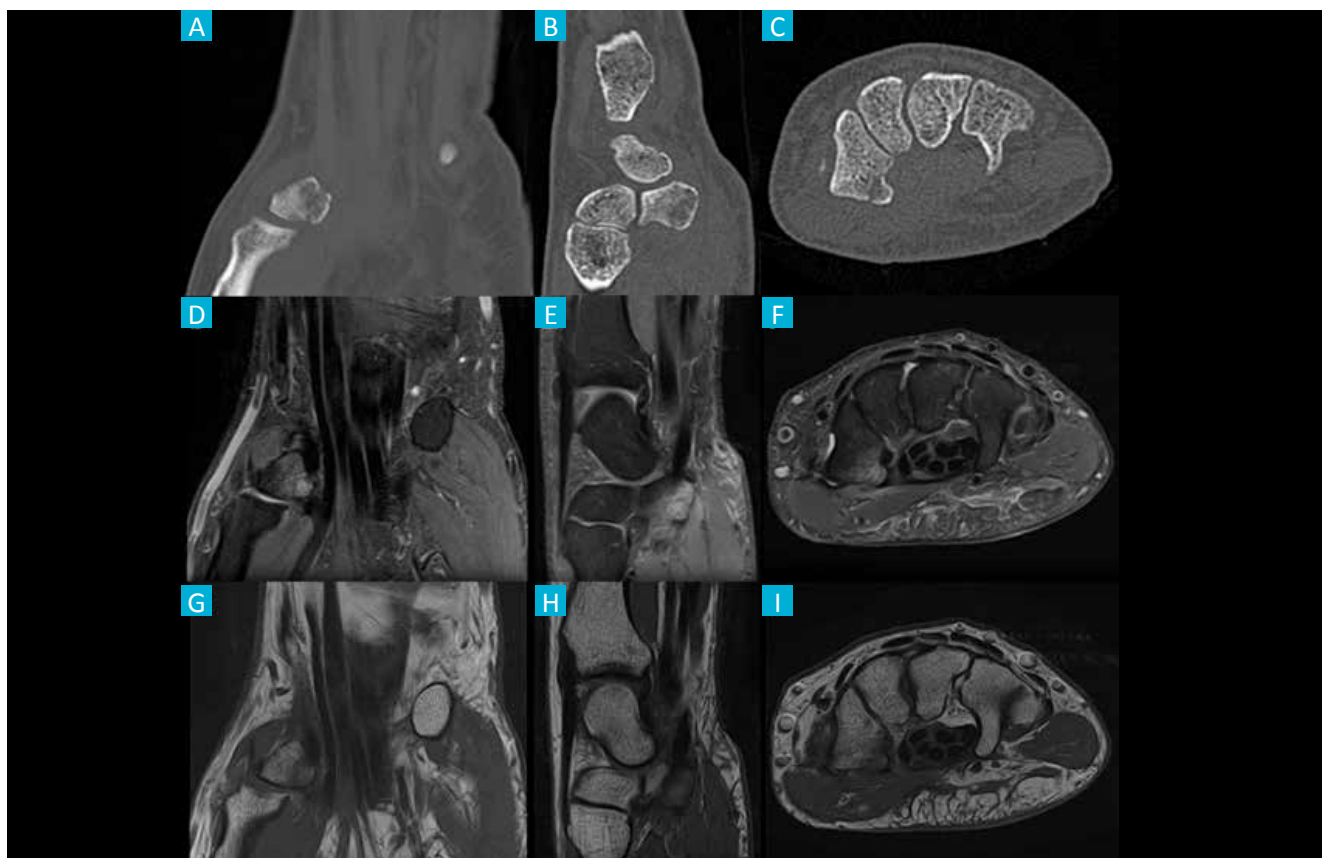


FIGURE 2. Left hand computed tomography scan (**A** - coronal, **B** - sagittal and **C** - axial views) and magnetic resonance imaging (**D** - coronal DP FS, **E** - sagittal DP FS, **F** - axial DP FS, **G** - coronal T1, **H** - sagittal T1 and **I** - axial T1) showing a non-displaced small volar fragment of the trapezium.

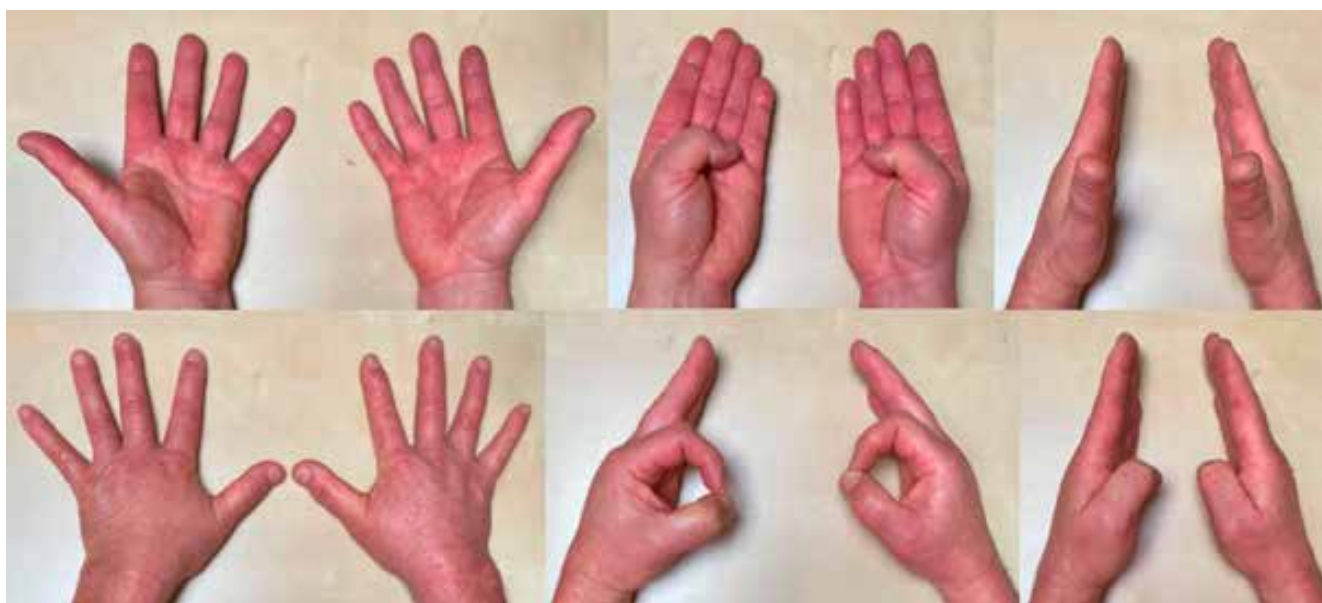

FIGURE 3. Follow-up at 2 months, following conservative treatment with short-arm thumb spica for six weeks: range of motion of both hands.

DISCUSSION

Trapezium plays a major role in thumb's function.⁴ The saddle shape of the trapeziometacarpal joint and its stabilizing ligaments have a role in providing the first ray with adequate mobility and stability needed for performing activities of everyday life.¹ According to the literature, nearly 50% of the trapezial fractures are a consequence of motorbike accidents,² as we reported in our case.

Walker *et al*⁸ presented a classification based on the anatomic appearance of the fracture, which had no relationship to either treatment or prognosis. The fracture's pattern - not mentioned on Walker's classification - is the one of the most important differences from other published papers.

Associated fractures are reported in 80% of cases¹ such as Bennett's fracture, Rolando's fracture, fractures of the scaphoid^{4,5} and distal radius fractures.³ Occasionally they may also be associated with ligament damage.⁶ The presented case had no associated injuries.

The clinical presentation can be quite variable depending on the displacement of the fracture and the involvement of the trapeziometacarpal joint. It could be minimal, with no gross deformity and almost full ROM of the thumb,⁹ like the presented case.

There is a high probability of misdiagnosing or missing these fractures in ED⁴ on account of their rarity and poor radiographic appearance on routine radiographs.⁵ Imaging consists of plain radiographs, but often undisplaced fractures can be imperceptible on these.^{4,6} Trapezial fractures diagnosis can be made by radiographs with specific projections^{4,5,9,10} such as Bett's view (true lateral view of the trapeziometacarpal joint),^{1,3} Robert's view (true anteroposterior view of the trapeziometacarpal joint) and carpal tunnel view.^{3,5} However, the sensibility of conventional plain radiographs is poor, varying from 18% to 67%.³ Thus, it is important to have a high clinical suspicion based on history and mechanism of injury.^{1,6}

Even with the initial negative projection radiograph, an additional CT scan^{3,4,6,7,10} or an MRI should be done to rule out occult fractures. CT scan is helpful in finding out the amount of displacement and the size of the fragments.³ MRI has additional value in detecting soft tissue injuries such as ligament ruptures.^{1,4}

Trapezium fractures are rare; this means there is lack of experience in treating those fractures.⁷ The literature reports several management options, and universal treatment protocol for trapezium fractures is not standardized.^{3,6} Non-displaced fractures with adequate

alignment of articular surface can be treated non-operatively; operative treatment is indicated for: displaced fractures, avulsion ridge fractures (as these are associated with higher risk of symptomatic nonunion) and highly comminuted fractures in high demand patients. Most frequent management and treatment are non-operative (thumb immobilization in a plaster or other metacarpal-finger types of immobilizations).^{2,6} The results of the conservative treatment range from successful to dismal.³ Operative treatment options include closed/open reduction and internal fixation.^{2,3,5,6,9,10} arthroscopy assisted internal fixation,^{2,3,6,10} external fixator,⁸ and fragment⁷ or trapezium excision.⁹ In our case, conservative treatment followed by physiotherapy played a major role to recover a normal painless ROM.

One of the main issues about our case was its inconclusive radiographs, highlighting that pain and swelling at carpal or the thumb after a motorcycle accident should never be underestimated and should lead the physician to think about the possibility of a trapezial fracture, and not just to other common carpal injuries.

Nowadays, the treatment of trapezium fractures is based on experience, but a standardized treatment protocol must be developed for future treatment.

AUTHORS CONTRIBUTION/ CONTRIBUIÇÃO AUTORAL

PB, CB and DM: Writing and revising the article

PB, CB e DM: Elaboração e revisão do artigo

RESPONSABILIDADES ÉTICAS

CONFLITOS DE INTERESSE: Os autores declaram a inexistência de conflitos de interesse na realização do presente trabalho.

FONTES DE FINANCIAMENTO: Não existiram fontes externas de financiamento para a realização deste artigo.

CONFIDENCIALIDADE DOS DADOS: Os autores declaram ter seguido os protocolos da sua instituição acerca da publicação dos dados de doentes.

CONSENTIMENTO: Consentimento do doente para publicação obtido.

PROVENIÊNCIA E REVISÃO POR PARES: Não comissionado; revisão externa por pares.

ETHICAL DISCLOSURES

CONFLICTS OF INTEREST: The authors have no conflicts of interest to declare.

FINANCIAL SUPPORT: This work has not received any contribution grant or scholarship.

CONFIDENTIALITY OF DATA: The authors declare that they have followed the protocols of their work center on the publication of data from patients.

PATIENT CONSENT: Consent for publication was obtained.

PROVENANCE AND PEER REVIEW: Not commissioned; externally peer reviewed.

REFERENCES

1. Arabzadeh A, Vosoughi F. Isolated comminuted trapezium fracture: A case report and literature review. *Int J Surg Case Rep.* 2021;78:363-8. doi: 10.1016/j.ijscr.2020.12.072.
2. De Nigris G, Falzarano G, Medici A, McCabe SJ, Predrag G, Meccariello ML, et al. A rare case of isolated trapezium fracture in motorcycle polytrauma patient in emergency department. *J Acute Dis.* 2016;5:252-4. Doi: 10.1016/j.joad.2016.03.016.
3. Martins IL, Vasques AL, Pereira FG, Brito F, Sousa R. Open Reduction and Fixation of Trapezium Fracture. *MOJ Orthop Rheumatol.* 2017;9:12-4.
4. Khan S, Gudhe M, Deshpande S, Singh PK, Patil B, Singhanian S. Missed Isolated Trapezium Fracture in Emergency Department. *Sch J Med Case Rep.* 2015;3:886-7.
5. Inston N, Pimpalnerkar A, Arafa M. Isolated fracture of the trapezium: an easily missed injury. *Injury.* 1997;28:485-8.
6. Ramoutar D, Katevu C, Titchener A, Patel A. Trapezium fracture - a common technique to fix a rare injury: a case report. *Cases J.* 2009;2:8304. doi: 10.4076/1757-1626-2-8304.
7. Beekhuizen S, Quispel C, Jasper J, Deijkers RL. The Uncommon Trapezium Fracture: A Case Series. *J Wrist Surg.* 2019;09:63-70. doi: 10.1055/s-0039-1683846.
8. Walker J, Greene T, Lunseth P. Fractures of the Body of the Trapezium. *J Orthop Trauma.* 1988;2:22-8.
9. Horch R. A new method for treating isolated fractures of the os trapezium. *Arch Orthop Trauma Surg.* 1998;117:180-2.
10. Wiesler E, Chloros G, Kuzma G. Arthroscopy in the Treatment of Fracture of the Trapezium. *Arthroscopy.* 2007;23:1248.e1-1248.e4.